En cada un dos debuxos do aparato locomotor hai dous nomes mal colocados. A ver se es quen de atopalos.

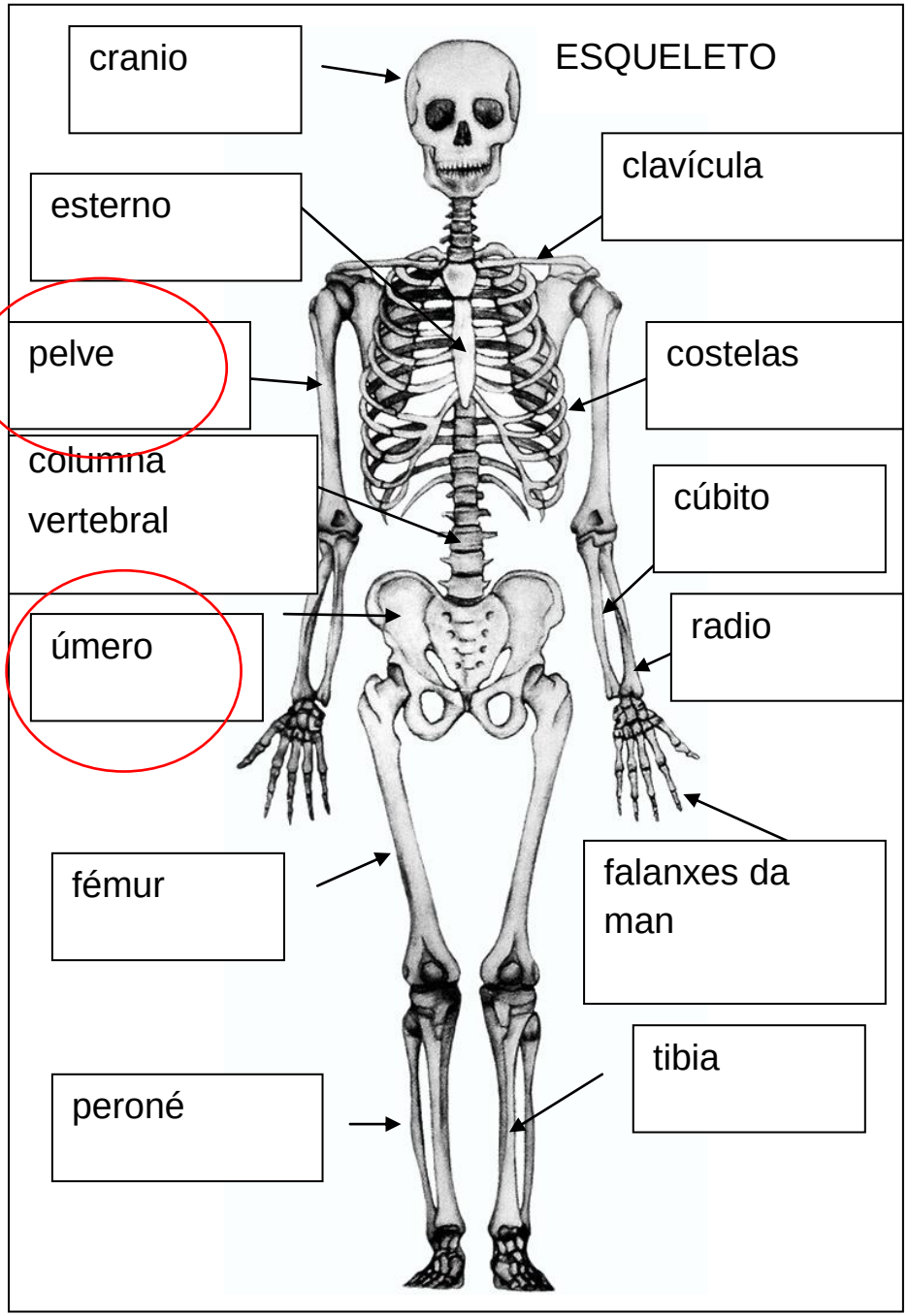
ESQUELETO
cranio
clavícula
esterno
pelve
costelas
columna vertebral
cúbito
úmero
radio
fémur
falanxes da man
tibia
peroné

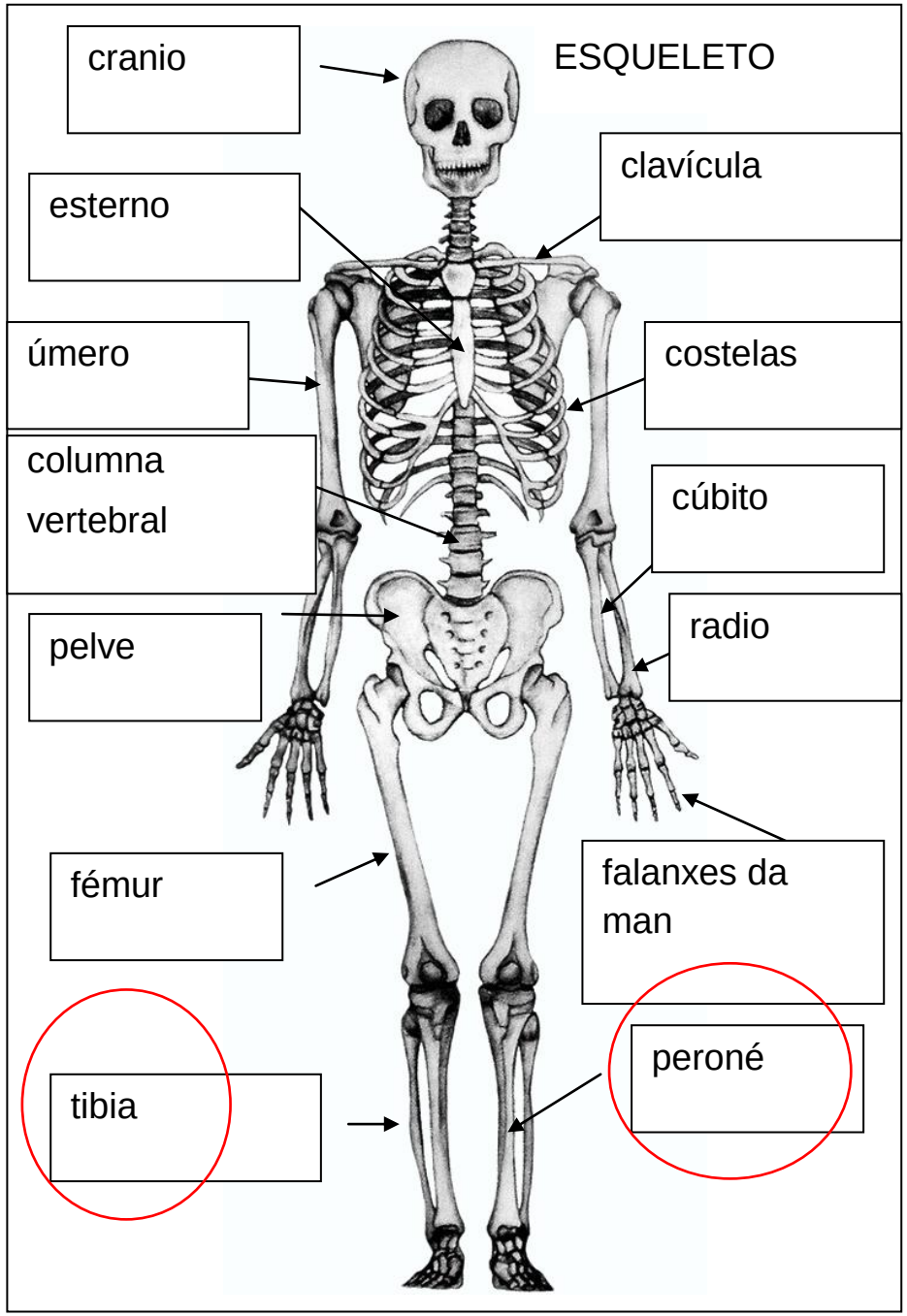
ESQUELETO
cranio
clavícula
esterno
úmero
costelas
columna vertebral
cúbito
pelve
radio
fémur
falanxes da man
tibia
peroné

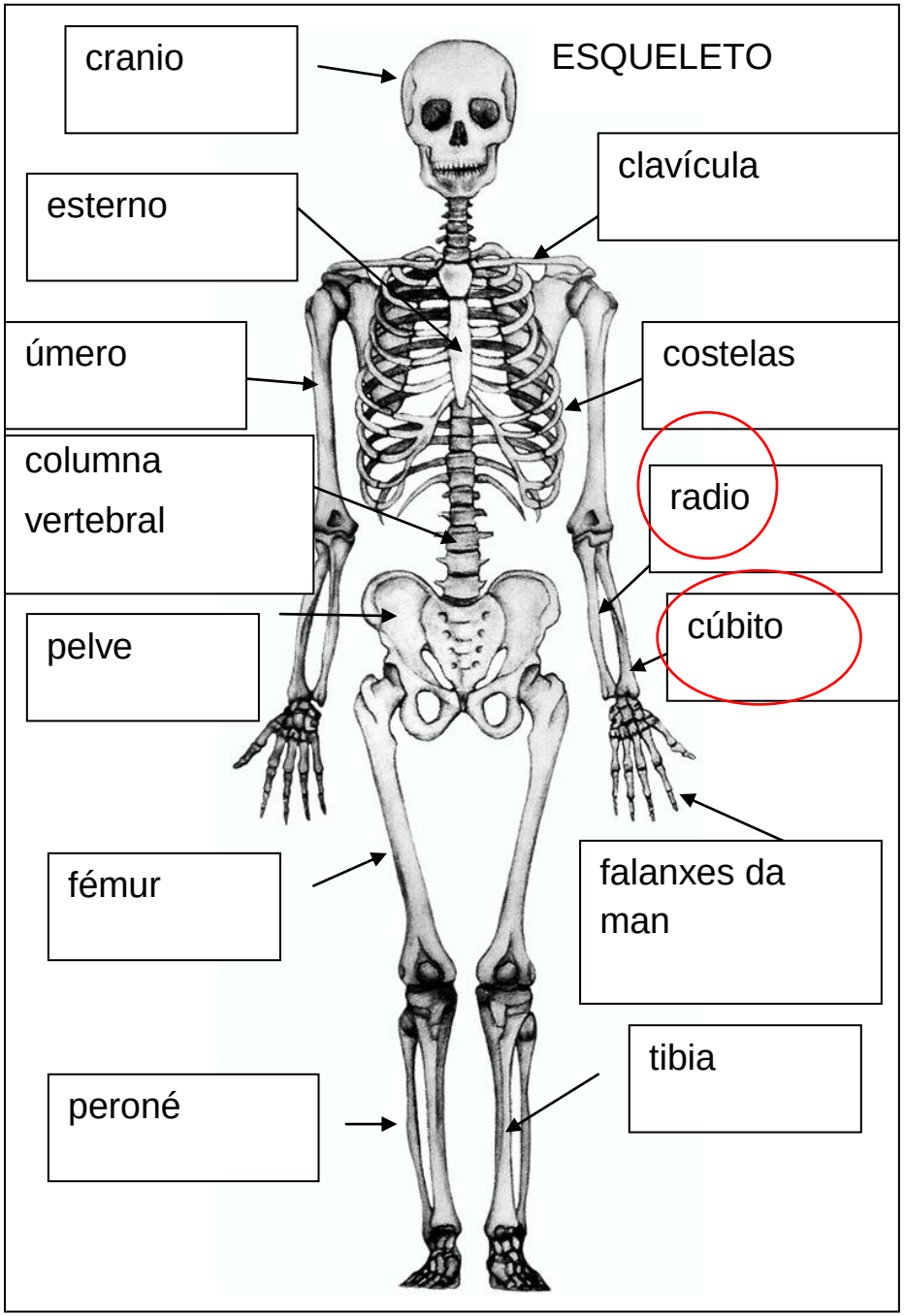
ESQUELETO
cranio
clavícula
esterno
úmero
costelas
columna vertebral
radio
cúbito
pelve
fémur
falanxes da man
tibia
peroné

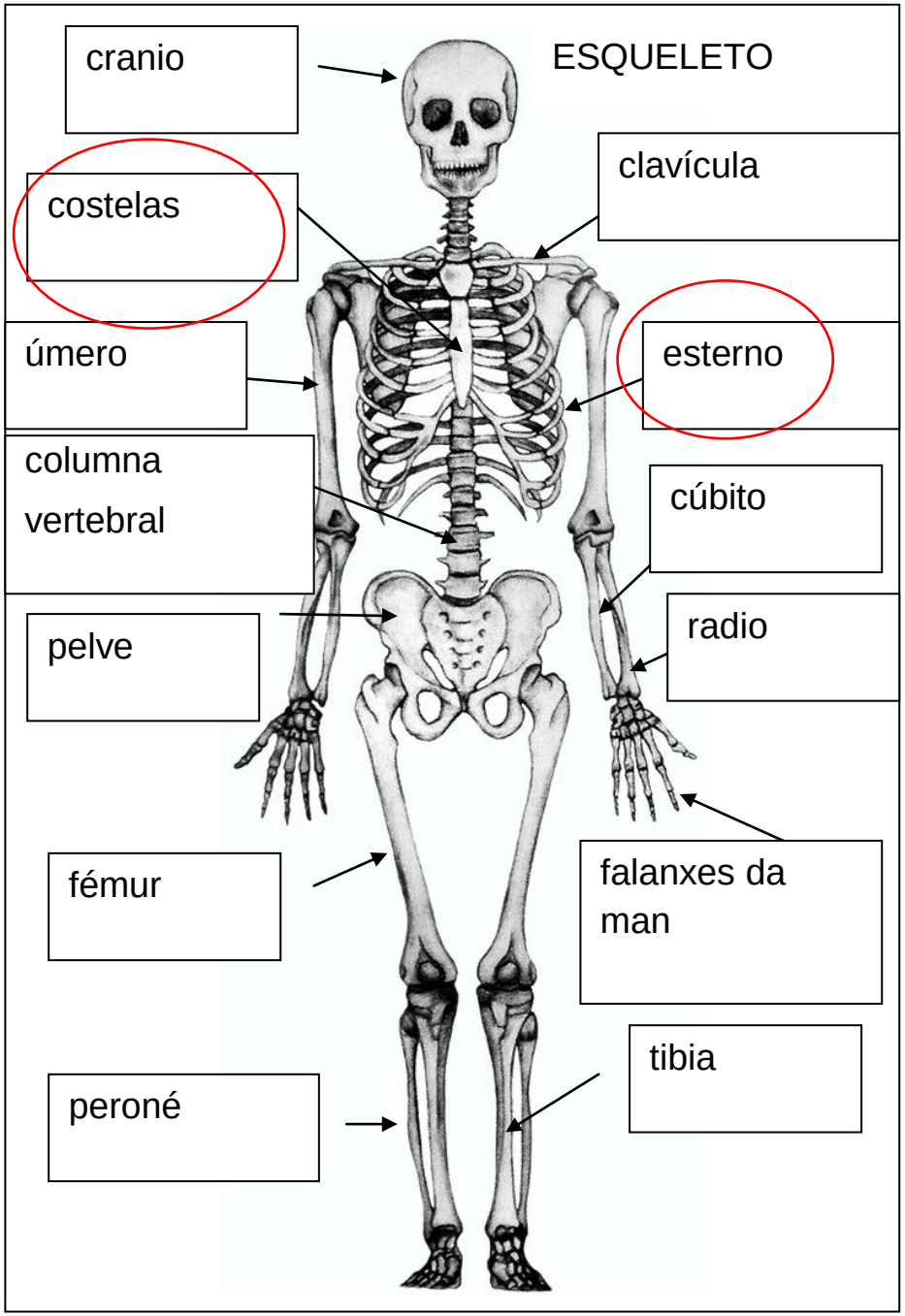
ESQUELETO
cranio
clavícula
costelas
úmero
esterno
columna vertebral
cúbito
radio
pelve
fémur
falanxes da man
tibia
peroné

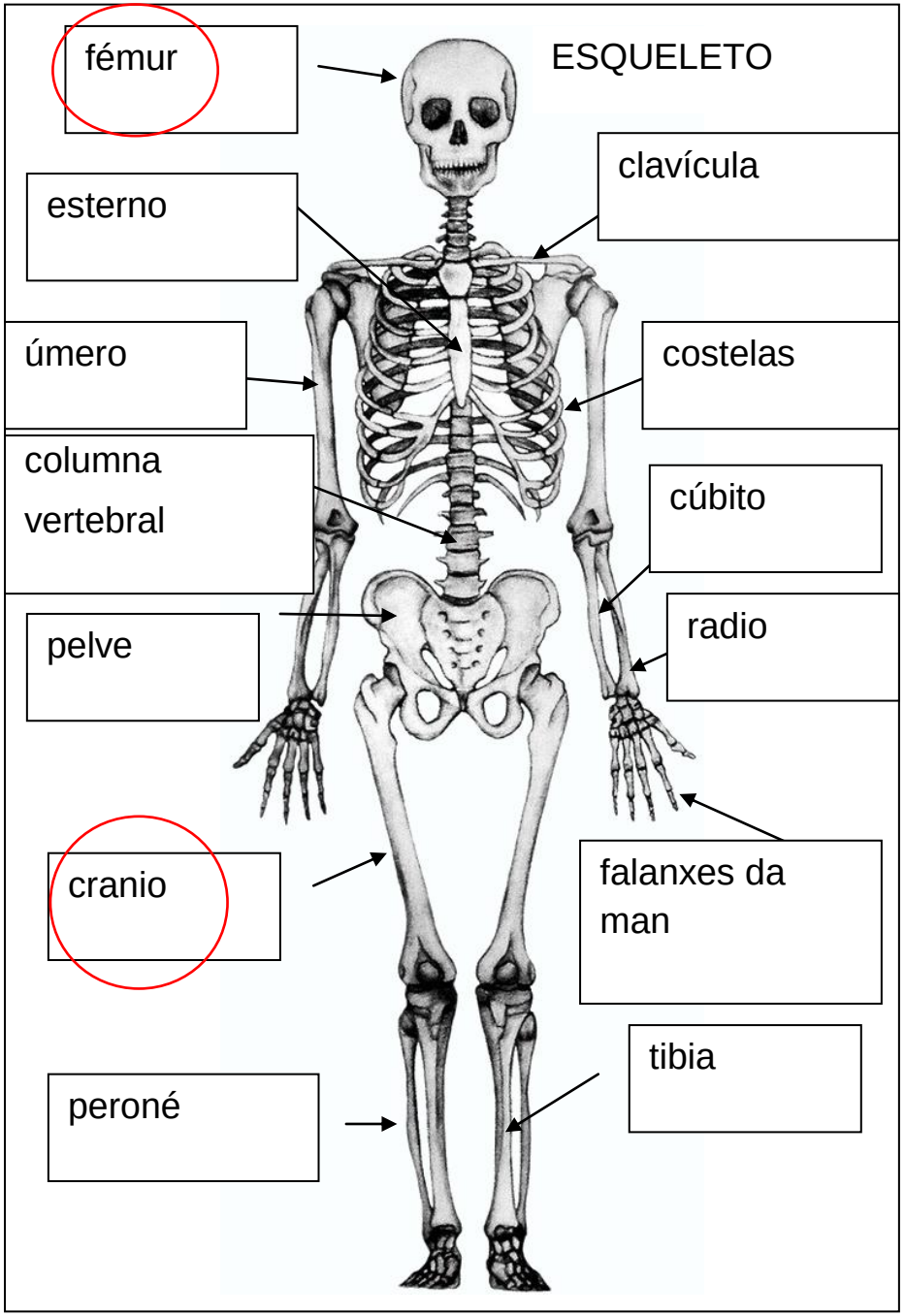
ESQUELETO
fémur
clavícula
esterno
úmero
costelas
columna vertebral
cúbito
pelve
radio
cranio
falanxes da man
tibia
peroné

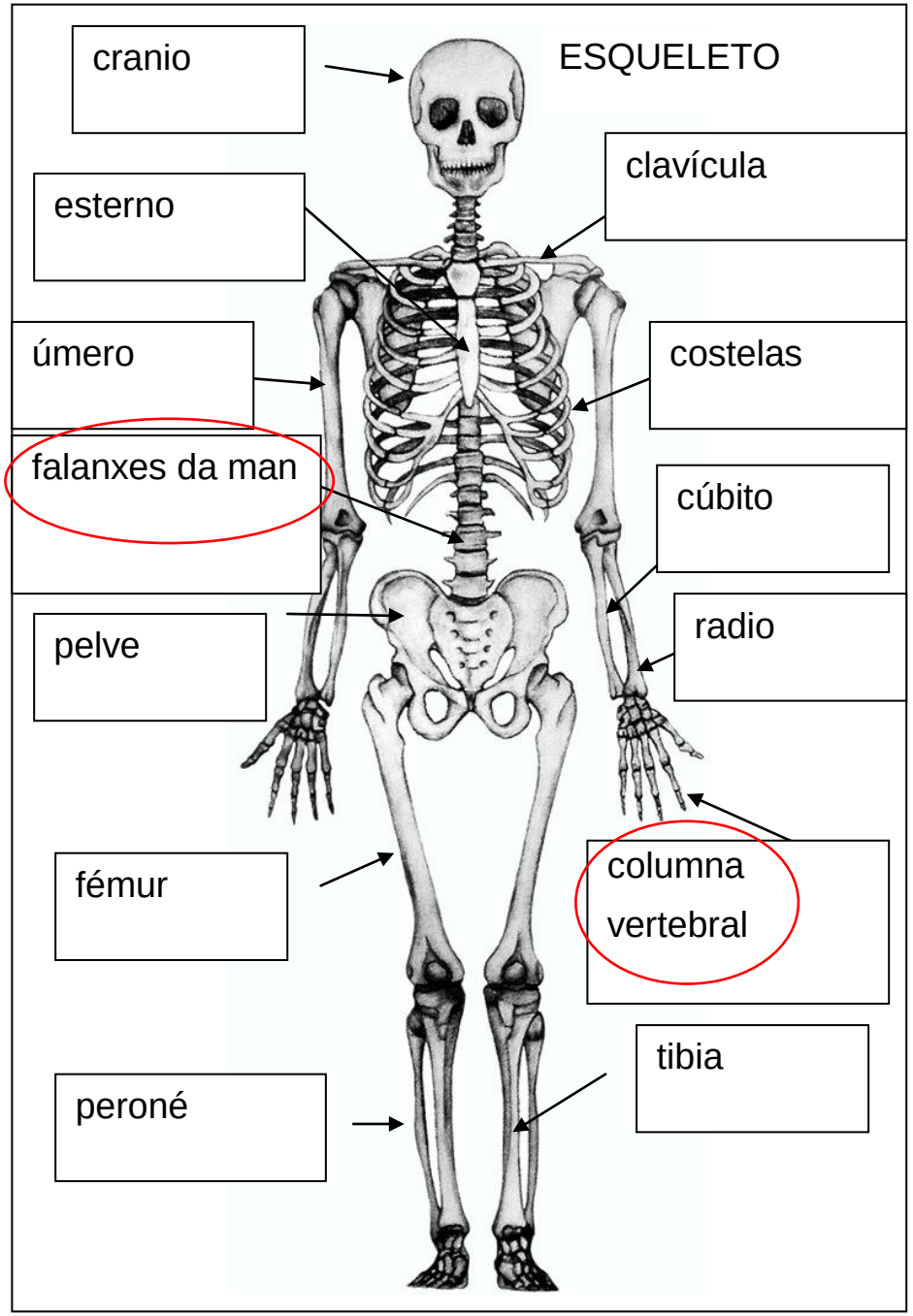
ESQUELETO
cranio
clavícula
esterno
úmero
costelas
falanxes da man
cúbito
pelve
radio
fémur
columna vertebral
tibia
peroné

deltoide
MÚSCULOS
bíceps
peitoral
glúteo
abdominais
xemelgos

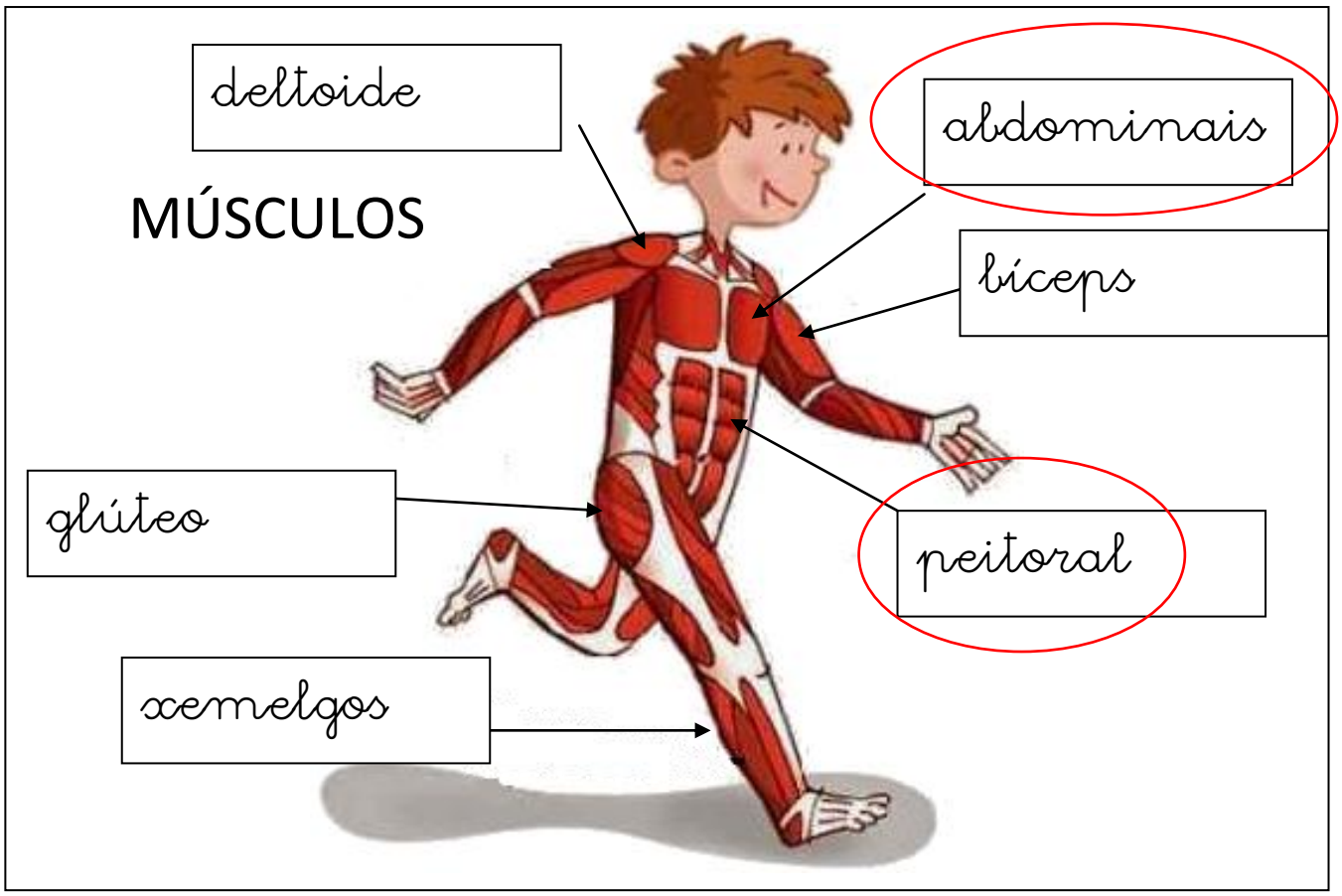
deltoide
MÚSCULOS
abdominais
bíceps
glúteo
peitoral
xemelgos

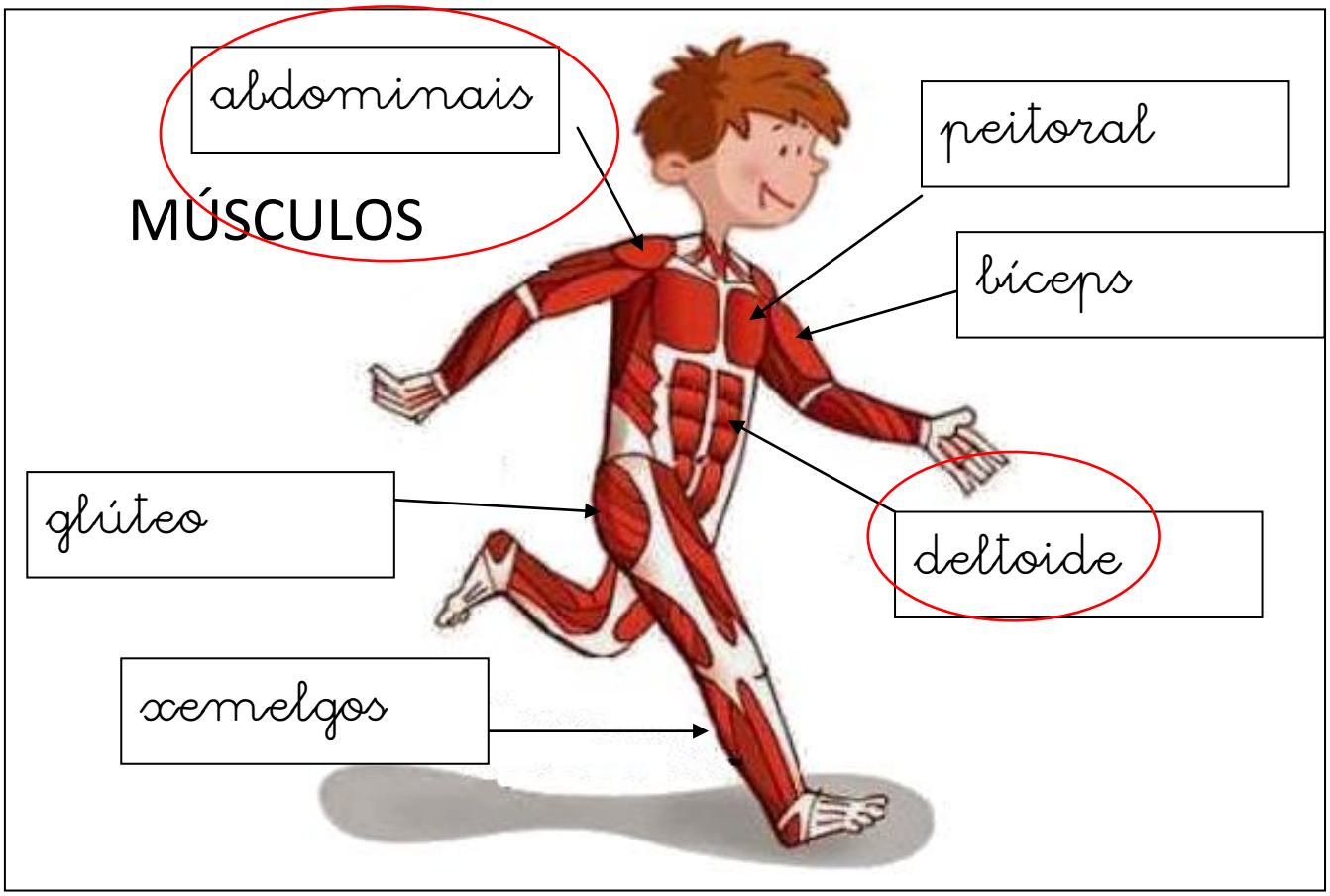
abdominais
MÚSCULOS
peitoral
bíceps
glúteo
deltoide
xemelgos

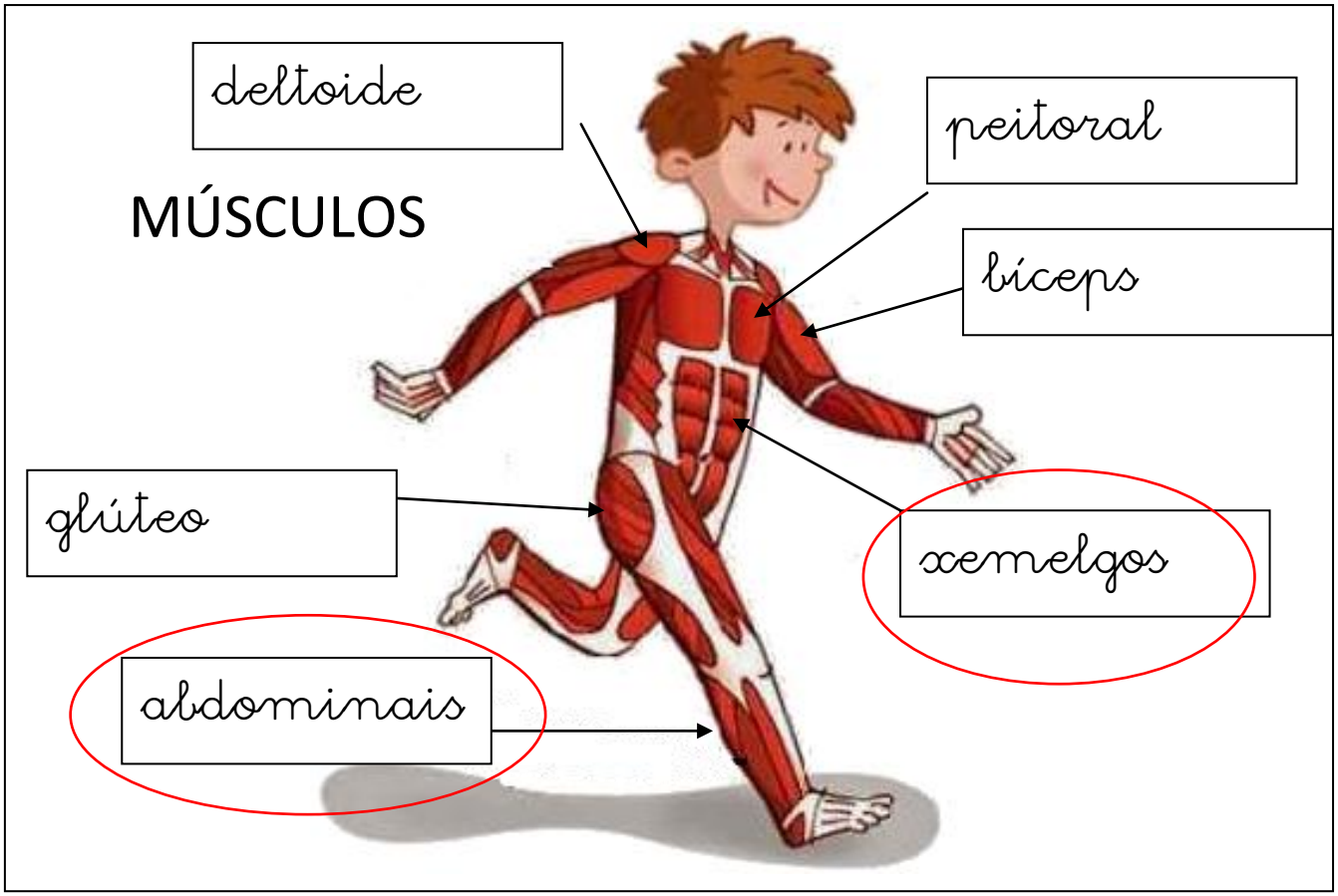
deltoide
MÚSCULOS
peitoral
bíceps
glúteo
xemelgos
abdominais

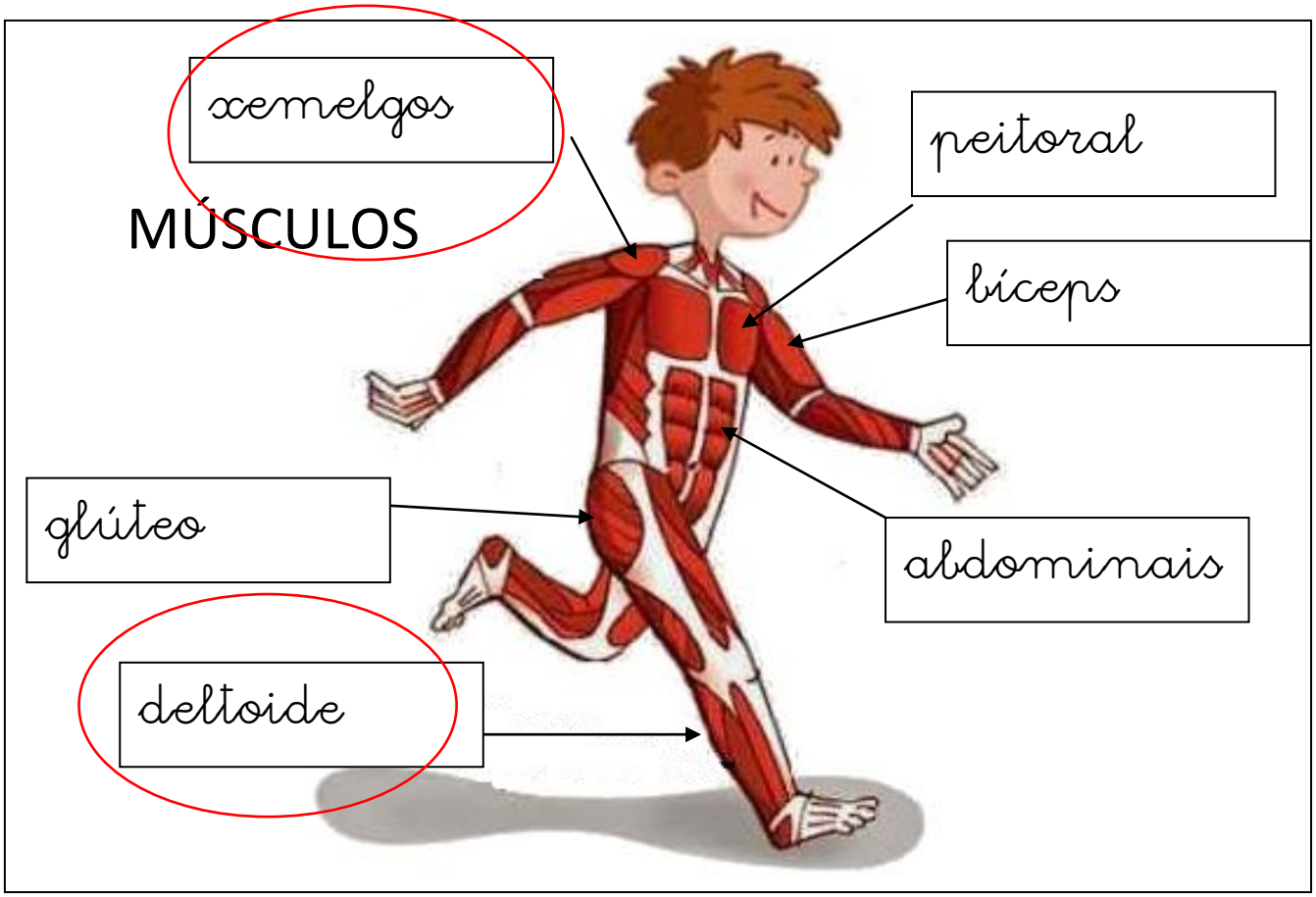
MÚSCULOS
xemelgos
peitoral
bíceps
glúteo
abdominais
deltoide

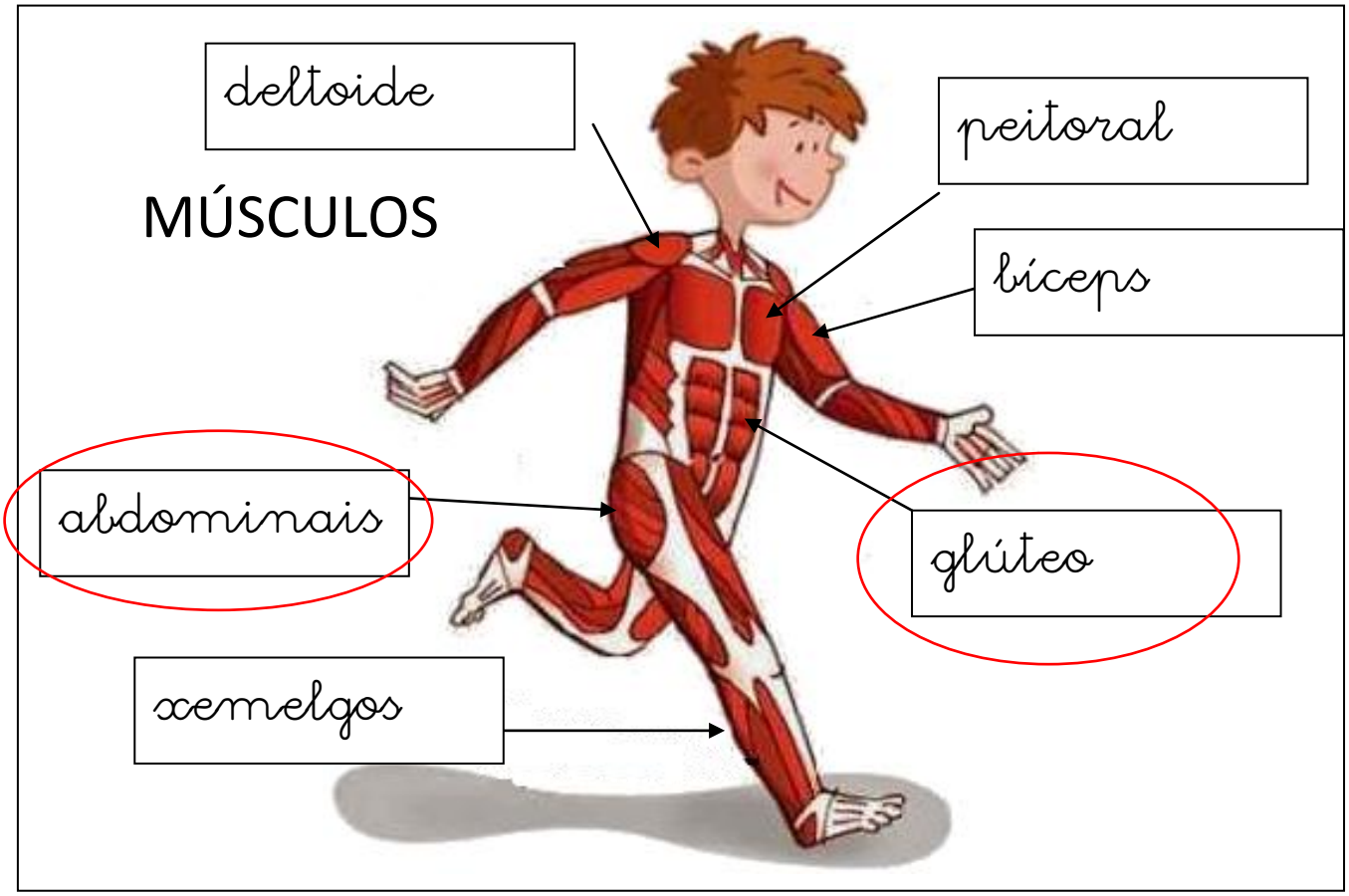
MÚSCULOS
deltoide
peitoral
bíceps
abdominais
glúteo
xemelgos